

Assessing the Toxicity of Benzalkonium Chloride on Common Carp (*Cyprinus carpio*): Impacts on Blood Cells, Gills, Intestines, and Liver

Mohammad Reza Rezaei^{a*}, Javad Kharkan^a, Mohammad Reza Yazdanshenas^a

^a Department of Environmental Engineering, Faculty of Natural Resources and Environment, University of Birjand, Birjand, Iran

ABSTRACT

The use of Benzalkonium Chloride and other alternative disinfectants increased during the COVID-19 pandemic. Therefore, it is crucial to consider their environmental effects. This study aims to investigate the toxicity potential of different concentrations of Benzalkonium Chloride on the blood cells, gills, intestines, and liver of common carp. For this purpose, 50 fish were divided into 5 groups of 10 (including one control group) and exposed to BAC concentrations of 0.10, 0.32, 0.58, and 0.75 mg/L for 28 days. The results showed that the RBC count (millions/mm³) in all exposed groups (Group B: 9.6 ± 1.07 ; Group C: 8.7 ± 0.78 ; Group D: 7.4 ± 0.96 ; Group E: 6.9 ± 0.55) was significantly lower ($p < 0.05$) than in the control group (13.9 ± 1.25). The cholesterol, triglyceride, protein, and albumin levels (mg/dl) in all experimental groups were lower than those in the control group. Conversely, the AST levels in all exposed groups were significantly higher ($P < 0.05$) compared to the control group. Gill damage included lamellar fusion, curvature, edema, and necrosis. In the liver, histological damage consisted of hepatocyte degeneration, central vein wall rupture, melano-macrophage aggregation, and blood vessel dilation. The results indicate that as Benzalkonium Chloride concentration increases from 0.10 to 0.78 mg/L, its toxicity effects on common carp also intensify. Therefore, before incorporating Benzalkonium Chloride into commercial products like cosmetics, its toxic effects should be thoroughly assessed to mitigate environmental harm.

ARTICLE INFO

Keywords:

Degeneration
Erythrocyte
Hematocrit
Intestine
Toxicity

Article history:

Received: 03 Oct 2024
Accepted: 08 Nov 2024

*Corresponding author

E-mail address:
mmrezaei@birjand.ac.ir
(M.R. Rezaei)

Citation:

Rezaei, M.R et al., (2025). Developing the glycerol carbonylation process using photocatalysis and 2-cyanopyridine as a water-reducing agent, *Sustainable Earth Trends*: 5(2), (11-26).

DOI: 10.48308/set.2024.237199.1073

1. Introduction

Environmental pollution caused by human industrial activities began in the early 20th century after industrialization. Humanity's insatiable need for industrialization has led to various inventions and the manufacturing of synthetic and semi-synthetic compounds. These inventions and the continuous exploitation of natural resources have caused varying degrees of environmental damage (Zhang et al., 2015). Disinfectants, both synthetic and non-synthetic, pose environmental hazards. In recent years, chemicals such as triclosan and triclocarban, commonly used in topical disinfectants, have come under public scrutiny due to environmental concerns when included in commercial detergent

products. In response, major manufacturers started removing triclosan from topical disinfectants and other products in 2011 (Ghaffar et al., 2021). Official bans on the use of triclosan and triclocarban in handwashing products in the United States were considered after 2017 (Food and Drug Administration, 2016). As these chemicals have been phased out from soaps and other hygiene products, there has been increased focus on the environmental impact of their replacements. Benzalkonium chloride (BAC) is one such alternative. The use of BAC and other disinfectants has surged during the COVID-19 pandemic (Hora et al., 2020; Zheng et al., 2020). BAC is a key member



of the quaternary ammonium compound group, which is widely used as biocides, corrosion inhibitors, pesticides, herbicides, and in cosmetics, pharmaceuticals, and personal care products (Kaczerewska et al., 2020). BAC is extensively used in aquaculture to prevent parasite growth, control algae, reduce the need for antibiotics, and as a general disease prevention strategy in fish farming. Additionally, it has been proposed as an alternative to tributyltin paints due to its anti-deposition properties (Antunes et al., 2016). Home use of BAC has resulted in its detection at concentrations ranging from 20 to 300 $\mu\text{g/L}$ in municipal wastewater (Clara et al., 2007; Martinez-Carballo et al., 2007). Due to its widespread use across various sectors, BAC can eventually enter aquatic environments, leading to both direct and indirect toxicity (Antunes et al. 2016). Studies have shown that BAC present in wastewater and aquatic environments can cause environmental toxicity in organisms like plankton and fish, and may also pose risks to carnivores and humans (Kwon et al., 2020). The toxic effects and risks of BAC exposure in animals are well documented (Kwon et al., 2019). Previous studies have shown that BACs can cause significant damage to cellular mitochondria, reproductive impairment in mammals, genotoxicity, and endocrine damage in aquatic organisms (Zhang et al., 2015). In addition, Antunes et al. (2016) stated that exposure of rainbow trout to BAC causes genotoxicity. It has been proven that the entry of BAC into the gills of fish can lead to disorders of the respiratory system and finally the death of the fish (Arianto et al., 2023).

Some quaternary ammonium compounds are known to induce genotoxic effects in mammalian cells, plants (Ferk et al., 2007), and crustaceans (Lavorgna et al., 2016). These compounds are of significant environmental concern due to their eco-toxicological characteristics and prevalence in wastewater and aquatic habitats. BAC typically causes cell damage through oxidative stress and interaction with membrane enzymes (Antunes et al., 2016). Various organisms, such as fish, can serve as biological indicators to monitor aquatic environments (Bongers et al., 1998). Common carp is a widely distributed freshwater fish and a valuable protein source. It ranks as the third most productive fish species in global aquaculture. Due to its sensitivity to changes in

hematological, biochemical, and enzymatic parameters, common carp is often used as a model organism to study the toxicity of various compounds (Saravanan et al., 2011). Histopathology involves the microscopic examination of cells and tissues to determine whether they are normal or abnormal, diagnose diseases, and develop new diagnostic tests and targeted treatments (Kandel and Castelli, 2020). This process examines changes in organs, tissues, and cells using techniques such as sectioning and staining (Mentese and Hancer, 2020). Previous studies have demonstrated that exposure to benzalkonium chloride in Nile fish causes various histopathological changes in the gills, kidneys, and liver, with the severity of these changes' dependent on the concentration of the chemical (Ikisa et al., 2019). Hematology is a branch of biology focused on the morphology of blood and blood-forming organs, providing crucial insights into the internal environment of organisms (Das et al., 2018). It identifies blood-related disorders based on cell counts and can impact various systems or organs, often affecting bone and associated tissues, leading to significant changes in bone marrow and adverse effects on blood cells. Consequently, this study aims to explore the toxic effects of different concentrations of BAC on the blood cells, gills, intestines, and liver of common carp.

2. Materials and Methods

2.1. Fish preparation

In this study, 50 common carp (weighing 100 ± 1.4 grams and measuring 18 ± 2.1 cm in body length) were acclimated to the aquarium environment for two weeks in the laboratory. These fish were sourced from breeding sites in Birjand, Iran, and transferred to the Limnology Laboratory at Birjand University's Faculty of Environment. Five 50-liter aquariums were used for the experiments. After disinfection and preparation, each aquarium was filled with 30 liters of chlorine-free city water. During the test period, water physicochemical parameters were monitored, including temperature ($22 \pm 1.7^\circ\text{C}$), pH (6.7 ± 0.2), electrical conductivity ($1382 \pm 24 \mu\text{S cm}^{-1}$), dissolved oxygen (4.7 ± 0.6 mg/L), and water hardness (407 ± 18 mg/L). The occurrence rate of BAC in Birjand city water was 0.0001 mg/L. The tests followed the OECD Guide No. 203 standard method (OECD, 2019).

To avoid the effects of fish excretions and maintain consistent toxin concentrations, the water in all aquariums was replaced daily with fresh water containing the same concentration of toxins.

2.2. Measurement of acute toxicity of BAC on common carp

The effect of acute toxicity of BAC on carp was investigated according to OECD guideline No. 233 to determine the median lethal concentration (LC50). First, a 1000 mg/L solution of BAC was prepared. Then, to measure acute toxicity and finally to find the average lethal concentration, a pre-test was performed in which different concentrations of BAC included 0.1, 0.3, 0.5, 0.7, 1, 5, and 10 mg/L was exposed to 10 fish for 96 hours. During the measurement period, the mortality rate was recorded at 24, 48, 72, and 96 hours in each concentration, and finally, based on the obtained data and the Probit software, the median lethal concentration was calculated.

2.3. Materials and tools needed

BAC with 80% purity and a density of 0.98 g/cm³, sourced from Chemi Store in China, was used in the limnology laboratory of Birjand University for the experiments. To prepare the BAC solution, 1.35 mg/L was measured from the stock solution and transferred into a 1,000 mL volumetric flask, then diluted to the mark with distilled water, resulting in a final concentration of 1,000 mg/L of BAC. The research employed various devices, including a pH meter (ST2100, Ohaus, Switzerland), an air pump (AP-320 model), an ultrasonic cleaner (vCLEAN1-L13 model), an automizer (Hitachi 917, Hitachi Company, Japan), an optical microscope (Nikon Eclipse E200), and a microtome (MH 733, China MOSS Company).

2.4. Design of experiments

Considering that LC_{50-96h} for BAC was 1.05 mg/L. 10, 30, 50 and 75% of LC_{50-96h} were selected as tested concentrations (Antunes et al., 2016; Said et al., 2023). Measurements were done with three repetitions. Common carp were exposed to different concentrations of BAC according to the following pattern:

- Control group: normal food and water
- Group B: 0.10 mg/L of BAC
- Group C: 0.32 mg/L of BAC

- Group D: 0.58 mg/L of BAC
- Group E: 0.75 mg/L of BAC

The fish were fed daily with food amounting to two percent of their body weight.

2.5. Hematology studies

At the end of the 28-day test period, six fish (weighing 100 ± 1.4 grams and measuring 18 ± 2.1 cm in body length) were anesthetized using clove extract. Blood samples were collected by cutting the caudal peduncle. Some of the blood was placed in vials containing anticoagulant for measuring blood factors, while the rest was transferred to vials without anticoagulant for serum factor analysis. After 2 to 3 minutes of slow movement, the samples were stored in the refrigerator. Immediately after blood collection, the number of red blood cells (RBCs) and white blood cells (WBCs) in the first sample were measured using a Neubauer slide and equations 1 and 2, respectively.

Eq. (1):

RBC count per mm³ of blood = Total number of RBCs counted in 5 small squares of the Neubauer slide × 200 × 10 × 5 (Equation 1)

Eq. (2):

Number of WBCs per mm³ of blood = $\frac{W}{4} \times 20 \times 10$

W: Number of WBCs in each Neubauer slide house

The hemoglobin (Hb) level was determined using Equation 3.

Eq. (3):

Hb (mg/dl) = $\frac{Ht}{3} + 1$

To determine the hematocrit (Ht) value, two-thirds of a capillary tube was filled with blood, sealed with hematocrit paste, and then centrifuged at 3000 rpm for 15 minutes.

Finally, the hematocrit was calculated as a percentage using Equation 4.

Eq. (4):

Ht(%) = (100 × Height of RBCs in the capillary tube) / (Height of RBCs and plasma)

2.6. Biochemical analysis and serum liver enzymes

The second blood sample was centrifuged at 3000 rpm for 15 minutes, and the serum was carefully extracted with a syringe and transferred to 1.5 ml Eppendorf tubes.

After centrifugation, 200 μ L of serum was collected for 1 ml of blood sample. Biochemical factors in the serum, including glucose, cholesterol, triglycerides, albumin, protein, uric acid, and creatinine, were measured using an autoanalyzer (Hitachi 917, Hitachi Company, Japan) and commercial kits from Pars Azmoun Company (registration code 34998, Iran). Additionally, liver enzymes such as aspartate aminotransferase (AST), alanine aminotransferase (ALT), and alkaline phosphatase (ALP) were also measured using the autoanalyzer.

2.7. Examining the morphology of erythrocyte

After 28 days, a blood smear was prepared, air-dried, fixed with methanol, and stained with Giemsa dye before being examined under a light microscope (Abbaszadeh et al., 2024).

2.8. Histopathological studies

Gill, intestine, and liver tissues fixed in 4% paraformaldehyde were dehydrated through a graded ethanol series (50-95%). The tissues were then embedded in paraffin and sectioned into 5 μ m thick slices using a microtome. The sections were stained with hematoxylin and eosin and examined under a light microscope (Zhang et al. 2022).

2.9. Statistical analysis

Data analysis was performed using SPSS software version 21 with one-way analysis of variance (ANOVA). When significant differences between treatments were detected, Duncan's test was applied to group the means with significant differences ($p < 0.05$). Graphs were generated using Origin software.

3. Results and discussion

3.1. Examining Changes in Hematological Parameters Across Different Study Groups

Fig. 1 illustrates the changes in hematological parameters across the different study groups. The results indicate that the RBC count (millions/ mm^3) in all treated groups (Group B: 9.6 ± 1.07 ; Group C: 8.7 ± 0.78 ; Group D: 7.4 ± 0.96 ; Group E: 6.9 ± 0.55) is significantly ($p < 0.05$) lower than in the control group (13.9 ± 1.25). The most substantial decrease in RBC count compared to the control was observed in

Group E (0.7 mg/L of BAC). These findings demonstrate that the toxicity of BAC is concentration-dependent, with higher concentrations resulting in greater toxicity. The WBC counts are presented in Fig. 1. The results show that the WBC count (thousands/ mm^3) in all treated groups (Group B: 25.4 ± 2.79 ; Group C: 25.1 ± 2.01 ; Group D: 25.8 ± 3.61 ; Group E: 28.4 ± 1.98) is higher than in the control group (24.4 ± 2.92). Notably, only Group E (0.7 mg/L of BAC) shows a significantly ($p < 0.05$) higher WBC count compared to the control. The Ht levels (%) for all studied groups (Group B: 20.5 ± 2.87 ; Group C: 18.6 ± 1.67 ; Group D: 16.3 ± 0.97 ; Group E: 15.8 ± 2.05) are lower than those of the control group (23.1 ± 1.61). The Ht (%) in Groups C (0.3 mg/L of BAC), D (0.5 mg/L of BAC), and E (0.7 mg/L of BAC) is significantly ($p < 0.05$) lower than in the control group, with the most substantial decrease observed in Group E. The Hb levels (gm/dl) in all treated groups (Group B: 12.7 ± 1.90 ; Group C: 10.5 ± 1.15 ; Group D: 10.4 ± 1.35 ; Group E: 10.1 ± 1.81) are lower than those in the control group (15.2 ± 1.36). Hb levels in Groups C (0.3 mg/L of BAC), D (0.5 mg/L of BAC), and E (0.7 mg/L of BAC) are significantly ($p < 0.05$) lower than in the control group. The results indicate that as BAC concentration increases, hemoglobin levels decrease more significantly, suggesting that higher BAC concentrations lead to greater toxicity.

In recent years, the European Commission has established strict criteria including ecotoxicological evaluations of the acute and chronic effects of pollutants on various aquatic organisms. Fish are valuable as biological indicators in ecotoxicological studies (Dani et al., 2019). Since the blood circulation system interacts closely with the external environment, hematological parameters are effective for detecting the impact of stressors and toxic substances. It has been suggested that fish hematology, biochemical changes, growth rates, and oxygen consumption rates should be used to assess pollutant toxicity. Damage to blood and blood-forming organs in fish can result from environmental conditions or water pollution. Blood cell factors, such as red and white blood cell counts, are useful indicators for evaluating responses to environmental stressors, which can lead to morphological changes and altered cell distribution (Chupani et al., 2017).

The results indicate that RBCs, hematocrit (Ht), and hemoglobin (Hb) levels are lower in all treated groups compared to the control. Increasing BAC concentrations from 0.10 to 0.75 mg/L lead to further reductions in RBCs, Ht, and Hb. Conversely, white blood cell (WBC) counts are elevated in all treated groups, with the most significant increase observed in Group E (0.7 mg/L BAC). This suggests that BAC toxicity increases with concentration, leading to anemia in fish due to decreased RBCs, Ht, and Hb (Yahya et al. 2019; Pourahmad et al. 2023). BAC, a quaternary ammonium compound (QAC), is commonly used as a disinfectant, antimicrobial, or surfactant in both industrial and household products. These substances can enter the environment, pass through sewage treatment systems, and eventually reach rivers. Due to its lipophilic nature, BAC is rapidly absorbed and accumulates in adipose tissues, particularly in aquatic species (Akram et al., 2022). The mechanism of action for quaternary ammonium compounds (QACs), including BAC, is believed to involve their impact on the cytoplasmic membrane, which regulates cell permeability. BAC can disrupt plasma membrane proteins, allowing other pollutants, such as heavy metals, to penetrate the cell, making it highly toxic to various organisms

(Lavorgna et al., 2016). BAC may also reduce cell activity in hematopoietic organs like the liver and bone marrow by affecting the cytoplasmic membrane. This decreased cell activity can lead to oxidative stress and reduced antioxidant defense, resulting in a decrease in red blood cells (RBCs) while increasing white blood cell (WBC) counts to bolster the immune response (Vasantharaja et al., 2015). Research indicates that BAC is highly toxic to aquatic life at elevated concentrations (Merchel Piovesan Pereira and Tagkopoulos, 2019). Said et al. (2023) found that various BAC concentrations significantly reduced RBCs and hemoglobin in *Oreochromis niloticus* compared to controls, while increasing WBC counts. They also noted that BAC induced oxidative stress in *Oreochromis niloticus*. Choi et al. (2020) reported that a BAC concentration of 4 mg/m³ increased RBCs, hematocrit (Ht), and hemoglobin (Hb) in rats, but higher concentrations led to oxidative damage. Gouda et al. (2022) observed that Linear Alkylbenzene Sulfonate (LAS) significantly decreased RBCs, Hb, and Ht in Nile tilapia, highlighting the impact of detergent exposure on blood cells. Akram et al. (2022) noted that Triclosan increased WBCs and Hb in large carp, attributing the decreased RBCs and Hb to BAC's hemolytic properties and the rapid oxidation of hemoglobin to methemoglobin.

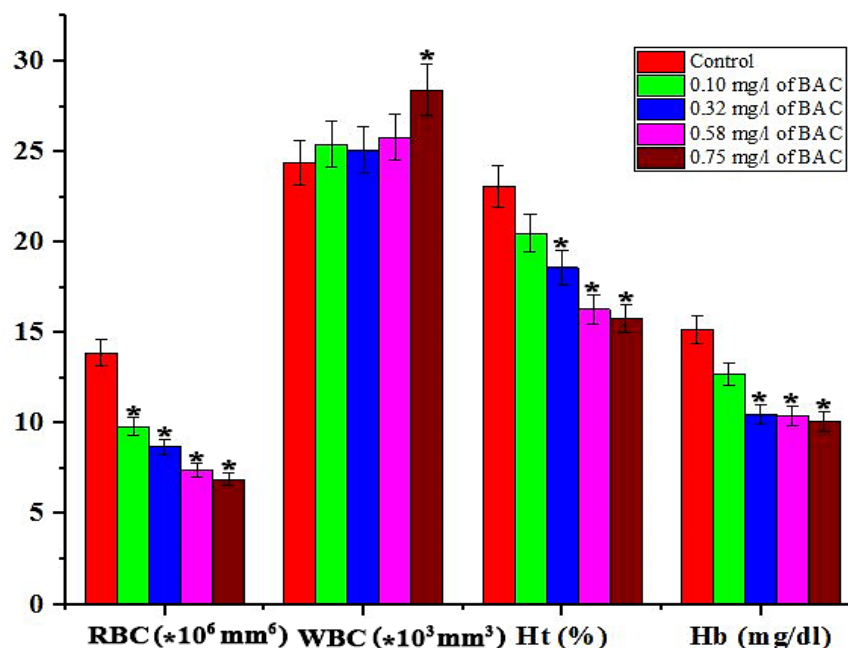


Fig. 1. Alterations in RBC and WBC counts, hematocrit, and hemoglobin levels in common carp after 28 days of exposure to benzalkonium chloride (BAC). (Control group: standard diet and water; Group B: 0.10 mg/L BAC; Group C: 0.32 mg/L BAC; Group D: 0.58 mg/L BAC; Group E: 0.75 mg/L BAC) (*: indicates a significant difference ($P < 0.05$) compared to the control group).

3.2. Examining the changes in the biochemical factors of the studied groups

Table 1 presents the changes in serum biochemical factors among the studied groups after 28 days. The results indicate that cholesterol, triglyceride, protein, and albumin levels (mg/dl) are lower in all treated groups compared to the control group. Specifically, Groups D (0.5 mg/L BAC) and E (0.7 mg/L BAC) show significantly ($P < 0.05$) lower levels than the control. The most pronounced decrease in these biochemical factors was observed in Group E. These findings suggest that the toxicity of BAC increases with higher concentrations. Glucose levels (mg/dl) in all treated groups increased significantly ($P < 0.05$) compared to the control group. The most substantial rise in glucose levels was observed in Group E (0.7 mg/L BAC). After 28 days, uric acid and creatinine levels (mg/dl) increased in all treated groups compared to the control group. Groups D and E showed significantly higher levels ($P < 0.05$) than the control. These results indicate that BAC toxicity is dependent on its concentration.

Serum biochemical factors are valuable indicators of physiological stress and overall fish health (Tuncsoy, 2021). Cholesterol, a key component of lipoproteins and steroid hormones, is typically synthesized by the liver and its levels in the serum can be affected by environmental pollutants that stimulate lipolysis. Research indicates that various pollutants can inhibit cholesterol synthesis in fish. This study also found that BAC reduces cholesterol levels across all tested groups compared to the control group (Table 1). The decrease in cholesterol observed with BAC exposure may be attributed to liver damage, increased cholesterol utilization for corticosteroid hormone synthesis, or enhanced gluconeogenesis (Tuncsoy, 2021). Triglycerides play a crucial role in the body by storing and providing energy to cells. During stress, organisms draw on lipid reserves to meet increased energy demands (Artacho et al., 2007). After 28 days of exposure, serum triglyceride levels in all studied groups were lower compared to the control group (Table 1). This reduction in triglycerides may be due to the body's attempt to meet energy needs through gluconeogenesis from non-glycogen sources (Tuncsoy, 2021). Proteins are continually produced and stored by the liver, so

a decrease in serum protein levels can indicate liver dysfunction, reduced food intake, or a weakened immune system (Alkaladi et al., 2015). The results revealed that protein levels in all studied groups decreased after 28 days compared to the control group, with the most significant reductions observed in the D and E groups. This reduction may be due to liver damage from high concentrations of BAC, leading to decreased serum protein levels. Additionally, BAC exposure could cause fish to utilize stored proteins for energy during stress or lead to protein loss through damage to intestinal and kidney tissues (Fig. 5) (De Souza et al., 2019). The results indicate that albumin levels were lower in all studied groups compared to the control group. A decrease in blood albumin can signal conditions such as liver or kidney disorders. Liver damage or inadequate nutrition can impair albumin production, while kidney damage can lead to excessive loss of albumin through urine, reducing blood levels (Hedayati et al., 2019). High concentrations of BAC may have decreased serum albumin by disrupting liver tissue in fish (Fig. 6). Sharma et al. (2021) found that varying concentrations of triclosan did not significantly affect serum albumin levels in *Labeo rohita*. However, Bera et al. (2020) reported that triclosan decreased serum albumin in catfish compared to controls. Akram et al. (2022) observed that a triclosan concentration of 2,500 $\mu\text{g/L}$ significantly increased blood cholesterol levels in carp after 15 days, attributing the increase to triclosan-induced stress. Li et al. (2018) reported that a triclocarban concentration of 90 mg/kg significantly elevated serum protein and cholesterol levels in mice compared to the control group.

Serum glucose levels are a key biomarker for assessing stress in fish (Kaya et al., 2015). In this study, glucose levels were significantly elevated in all groups compared to the control group after 28 days. BAC may have inhibited the activity of enzymes such as phosphofructokinase, lactate dehydrogenase, and citrate kinase under stress, leading to increased serum glucose levels. Elevated glucose levels suggest reduced glycogen storage (Abdel-Khalek et al., 2015). This indicates that BAC at varying concentrations may impair glycolysis, resulting in decreased glycogen reserves (Shaluei et al., 2013). Uric acid and serum creatinine are critical indicators

of muscle metabolism and kidney function. Elevated levels of these substances can signal disruptions in filtration processes and kidney tissue damage (Akram et al., 2021). Creatinine, a byproduct of creatine metabolism, is a metabolic waste product generated by muscle activity. It is filtered by the kidneys and excreted in urine (Penuela et al., 2021). High creatinine levels can indicate kidney cell damage and impaired glomerular filtration (Julinta et al., 2019). The results demonstrate an increase in uric acid and creatinine levels in all studied groups compared to the control group after 28 days (Table 1). This suggests that elevated BAC concentrations may lead to

higher uric acid and creatinine levels in fish due to kidney cell damage. In related studies, Said et al. (2023) found that BAC increased serum glucose and creatinine in Nile tilapia after 42 days. Akram et al. (2022) reported that triclosan raised uric acid and creatinine levels in carp, attributing this to kidney tissue damage. Penuela et al. (2021) observed increased serum creatinine and uric acid in *Pseudoplatystoma magdaleniatum* fish due to triclosan exposure. Dar et al. (2024) noted that triclosan decreased glucose and uric acid levels in *Cirrhinus mrigala*, with increased triclosan concentration correlating with higher toxicity levels.

Table 1. Alterations in biochemical factors of common carp following 28 days of exposure to benzalkonium chloride (BAC). (Control group: standard diet and water; Group B: 0.10 mg/L BAC; Group C: 0.32 mg/L BAC; Group D: 0.58 mg/L BAC; Group E: 0.75 mg/L BAC) (*: denotes a significant difference ($P < 0.05$) from the control group).

Parameters	Days	Control	Group B	Group C	Group D	Group E
Cholesterol(mg/dl)	28	244.4 ± 29.32	231.19 ± 18.49	218.02 ± 15.26	161.09 ± 17.71*	151.06 ± 13.59*
Triglyceride (mg/dl)	28	1131.1 ± 147.04	1122.8 ± 89.76	1087.5 ± 76.12	997.7 ± 49.88*	861.4 ± 77.52*
Protein (mg/dl)	28	1.48 ± 0.17	1.43 ± 0.07	1.41 ± 0.12	1.33 ± 0.09*	1.31 ± 0.09*
Albumin (mg/dl)	28	0.57 ± 0.03	0.51 ± 0.06	0.49 ± 0.05	0.39 ± 0.01*	0.37 ± 0.02*
Glucose (mg/dl)	28	49.99 ± 3.99	89.07 ± 9.79*	89.89 ± 12.58*	101.39 ± 6.08*	126.23 ± 17.67*
Uric Acid (mg/dl)	28	16.25 ± 1.95	18.31 ± 2.56	20.37 ± 2.64	22.43 ± 1.79*	24.49 ± 2.69*
Creatinine (mg/dl)	28	0.22 ± 0.02	0.25 ± 0.02	0.28 ± 0.01	0.33 ± 0.03*	0.35 ± 0.02*

3.3. Assessing variations in liver enzyme levels across different study groups

Fig. 2 illustrates the changes in liver enzyme levels across different study groups. The results indicate that the AST levels are significantly higher ($P < 0.05$) in all treated groups (Group B: 215.47 ± 19.39 ; Group C: 242.64 ± 33.96 ; Group D: 309.91 ± 21.69 ; Group E: 324.44 ± 58.39) compared to the control group (149.37 ± 23.89). The most pronounced increase in AST was observed in Group E (0.7 mg/L BAC). These findings suggest that AST levels rise with increasing BAC concentration, indicating that BAC toxicity is concentration-dependent. The results indicate that ALT levels in all treated groups (Group B: 89.71 ± 9.86 ; Group C: 92.13 ± 11.05 ; Group D: 140.05 ± 29.41 ; Group E: 164.82 ± 44.50) are elevated after 28 days compared to the control group (73.46 ± 12.48). Specifically, the ALT levels in Groups D and E are significantly higher ($P < 0.05$) than those in the control group. The results indicate that ALP levels are higher in all treated groups (Group B: 52.03 ± 12.48 ; Group C: $70.09 \pm$

9.81 ; Group D: 78.82 ± 14.15 ; Group E: 76.20 ± 13.71) compared to the control group (37.14 ± 7.05). Specifically, ALP levels in Groups C, D, and E are significantly higher ($P < 0.05$) than in the control group. These findings suggest that BAC toxicity increases with higher concentrations.

The liver plays a crucial role in detoxification, leading to high concentrations of transaminases in liver cells. Damage to liver tissue typically results in elevated levels of AST and ALT (Hatami et al., 2019). ALP is another key liver enzyme, located in the cell membrane, and is vital for detoxification processes. This enzyme is produced by the bile duct cells in the liver (Giang et al., 2019). An increase in ALP following BAC exposure may result from disruptions to the plasma membrane and liver necrosis (Fig. 6, Hatami et al., 2019). Additionally, BAC-induced oxidative stress can accelerate metabolite movement and cell necrosis, leading to higher ALP levels in the blood (Lakra et al., 2021). Our study observed that BAC exposure increased serum levels of ALP, AST, and ALT after 28 days (Fig. 2).

Previous research has reported similar increases in AST and ALT levels in response to triclosan in *Cyprinus carpio*, *Ctenopharyngodon idella*, and *Cirrhinus mrigala* (Dar et al., 2020a; Dar et al., 2020b). Penuela et al. (2021) found that triclosan decreased ALP levels in *Pseudoplatystoma magdaleniatum* after 14 days. Hemalatha et al. (2019) reported increases in ALT, AST, and ALP levels in

Catla catla due to triclosan. Choi et al. (2020) noted that BAC reduced ALP levels in rat blood. Aboulhoda et al. (2020) found that selenium oxide nanoparticles increased ALP and AST levels in mice, attributing this to liver structural damage. Elkeiy et al. (2020) reported that chitosan nanoparticles elevated AST and ALT levels in rats, linking this to oxidative stress and liver cell necrosis.

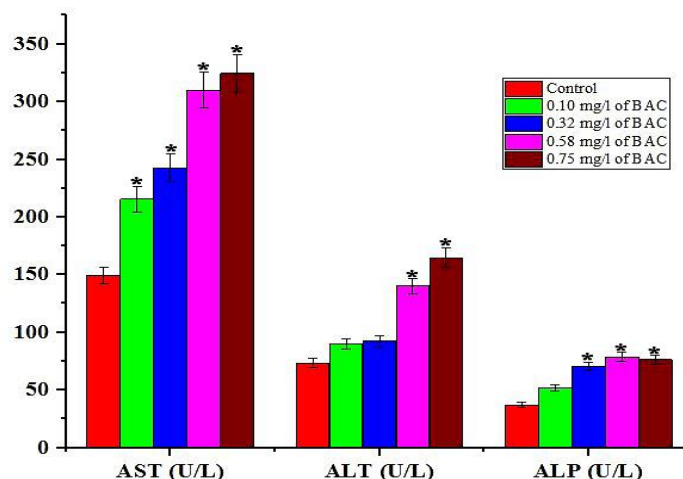


Fig. 2. Alterations in liver enzyme levels in common carp after 28 days of exposure to benzalkonium chloride (BAC). (Control group: standard diet and water; Group B: 0.10 mg/L BAC; Group C: 0.32 mg/L BAC; Group D: 0.58 mg/L BAC; Group E: 0.75 mg/L BAC) (*: indicates a significant difference ($P < 0.05$) from the control group).

3.4. Investigating changes in the morphology of erythrocytes of different studied groups

Fig. 3 illustrates the morphological changes in erythrocytes across the different study groups. The results reveal alterations such as deformation (DC) and vacuolation (VC) in the erythrocytes. The most significant morphological changes are observed in common carp exposed to 0.78 mg/L of BAC, indicating that BAC toxicity increases with higher concentrations. In toxicological research, examining erythrocyte morphology is crucial for assessing the impact of pollutants on aquatic organisms' health. The results reveal that erythrocytes exhibit deformation and vacuolation when exposed to pollutants. The most significant morphological changes in erythrocytes occur at a BAC concentration of 0.78 mg/L, indicating that BAC toxicity escalates with increasing concentration (Fig. 2). Erythrocytes, which have a negatively charged surface due to carboxyl groups, can interact with pollutants like BAC, leading to damage and alterations in cell morphology (Zheng et al., 2013). Previous studies have shown that triclosan induces abnormalities such as

microcytes, leptocytes, and spherocytes in carp by disrupting erythrocyte membranes (Akram et al., 2022). Additionally, triclosan has been reported to cause micronucleus formation and apoptosis in *Oreochromis niloticus* erythrocytes (Vijitha et al., 2017) and induce morphological changes in the erythrocytes of *Lithobates catesbeianus* (Curi et al., 2019). Cement dust has also been noted to disrupt erythrocyte morphology in Wistar rats (Owonikoko et al., 2022).

3.5. Investigating the histological damage of fish gills

Fig. 4 illustrates various histological damages in the gills of common carp after 28 days of exposure to BAC. Notable injuries include lamellar fusion, lamellar synechia, aneurysms, curvature, edema, and necrosis. The results indicate that as BAC concentration increases, the severity of gill damage also escalates, demonstrating that BAC toxicity is concentration-dependent (Table 2). Severe histological damage, including lamellar fusion, lamellar synechia, aneurysms, curvature, edema, and necrosis, is observed in the gills of fish exposed to 0.7 mg/L BAC.

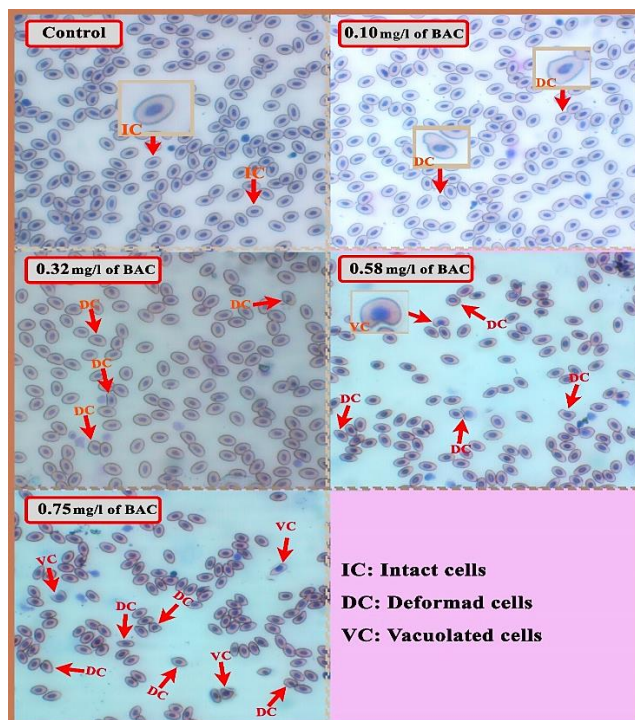


Fig. 3. Morphological alterations in erythrocytes of common carp after 28 days of exposure to benzalkonium chloride (BAC). (Control group: standard diet and water; Group B: 0.10 mg/L BAC; Group C: 0.32 mg/L BAC; Group D: 0.58 mg/L BAC; Group E: 0.75 mg/L BAC).

In this study, the histopathological examination of gill tissue from fish exposed to BAC revealed various lesions, including lamellar fusion, lamellar synechiae, aneurysms, curvature, edema, and necrosis. The severity of these damages increased with higher BAC concentrations. Since fish gills are the primary organs in contact with pollutants in aquatic environments, their histological assessment is crucial. Gills facilitate gas exchange, maintain ionic balance, and regulate osmotic processes (Ghaffar et al., 2018). Each gill arch comprises large filaments with two rows of secondary lamellae arranged vertically (Ikisa et al., 2019). BAC exposure likely induces excessive blood flow within the lamellae, leading to lamellar fusion and shortening. Edema, which occurs when gaps form between the epithelium and

blood vessels, serves as a defensive response to minimize gill damage (Ikisa et al., 2019). The accumulation of blood in the secondary lamellae can cause aneurysms (Pane et al., 2004). Previous research by Ikisa et al. (2019) indicated that BAC induces hyperplasia, lamellar fusion, and cell necrosis in Nile tilapia gill tissue. Similarly, O’Brown et al. (2018) found that triclosan led to lamellar shortening and adhesion in zebrafish gills, while Arman (2021) reported aneurysms, hyperplasia, and lamellar adhesion in zebrafish. Priyatha and Chitra (2018) observed mild necrosis in the gills of *Anabas testudineus* exposed to triclosan. These findings align with other studies (Hemalatha et al., 2019; Capkin et al., 2017; Nan et al., 2023).

Table 2. Histological damage in the gills of common carp after 28 days of exposure to benzalkonium chloride (BAC). (Control group: standard diet and water; Group B: 0.10 mg/L BAC; Group C: 0.32 mg/L BAC; Group D: 0.58 mg/L BAC; Group E: 0.75 mg/L BAC). The observed damage includes lamellar synechiae (LS), fusion of lamellae (F), curvature (CU), edema (Oe), aneurysm (An), and necrosis (N). No change (-), mild (+), moderate (++) and severe (+++).

Gill	Histological changes					
	LS	F	CU	Oe	An	N
Control	-	-	-	-	-	-
Group B	-	-	-	-	+++	-
Group C	-	++	++	-	-	-
Group D	+++	++	-	-	+++	-
Group E	+++	+++	++	+	++	+

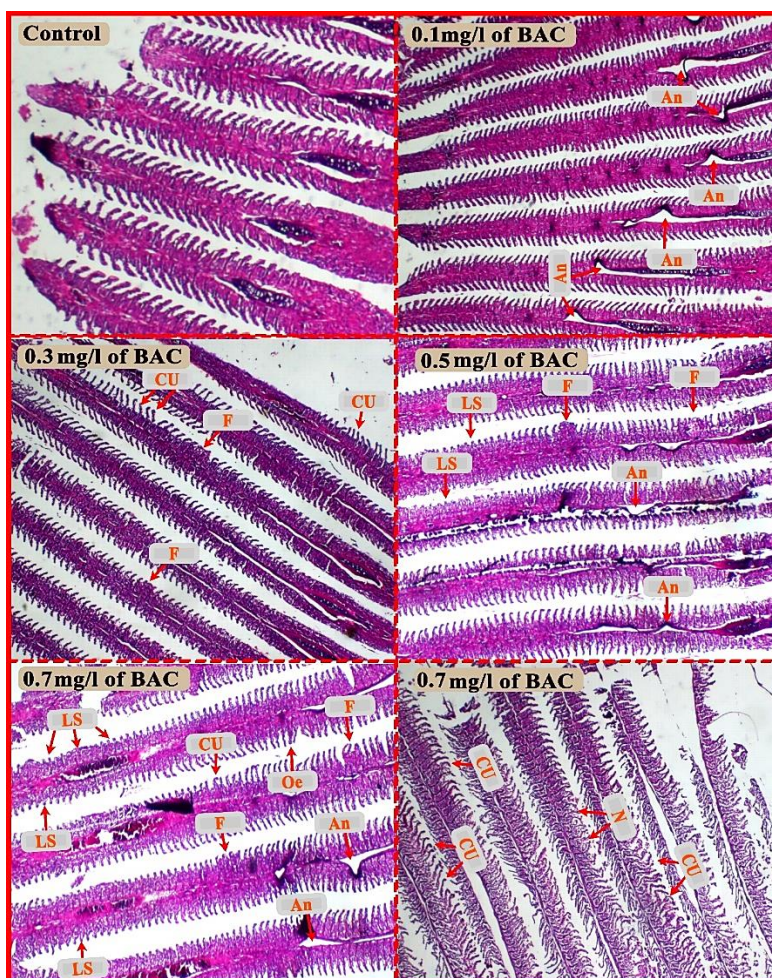


Fig. 4. Histological damage in the gills of common carp after 28 days of exposure to benzalkonium chloride (BAC). (Control group: standard diet and water; Group B: 0.10 mg/L BAC; Group C: 0.32 mg/L BAC; Group D: 0.58 mg/L BAC; Group E: 0.75 mg/L BAC). The observed damage includes lamellar synechia (LS), fusion of lamellae (F), curvature (CU), edema (Oe), aneurysm (An), and necrosis (N).

3.6. Investigating fish intestine tissue damage

Fig. 5 illustrates various histological damages in the intestinal tissue of common carp after 28 days of exposure to BAC. These damages include expansion of the villi structure, an increase in the number of blood cells, a rise in goblet cells, swelling of goblet cells, and necrosis. The severity of these damages is most pronounced at a BAC concentration of 0.7 mg/L. This indicates that BAC toxicity intensifies with increasing concentrations (Table 3). The intestine plays a crucial role in regulating osmotic pressure and is one of the first organs to encounter contaminants in food and water. However, the effects of BAC exposure on intestinal tissue are not well-documented (Kaya et al. 2016). In this study, exposure to BAC resulted in several histopathological changes in the intestinal tissue, including an increase in the number of goblet cells, goblet cell swelling, an increase in blood cells, villi expansion, and necrosis (Fig.

5). The swelling and proliferation of goblet cells are part of the fish's defense mechanisms against the toxic effects of BAC (Suganthi et al. 2015). Similar effects have been reported in previous studies with different pollutants. Abd El-Naby et al. (2020) observed that chitosan nanoparticles increased the number of goblet cells and caused cell vacuolation in the intestinal tissue of *Oreochromis niloticus*. Kakakhel et al. (2021) reported that silver nanoparticles induced degeneration, necrosis, and loss of epithelial cells in the intestinal villi of carp. Kaya et al. (2016) found that ZnO nanoparticles caused goblet cell swelling, hyperplasia, and vacuolation in the intestine of *Oreochromis niloticus* after 14 days. Similarly, Mansouri et al. (2017) reported that titanium dioxide nanoparticles led to goblet cell swelling, an increase in goblet cell numbers, and villi expansion in the intestines of common carp. Johari et al. (2015) found that silver nanoparticles caused erosion and fusion of intestinal villi in *Oncorhynchus mykiss*.

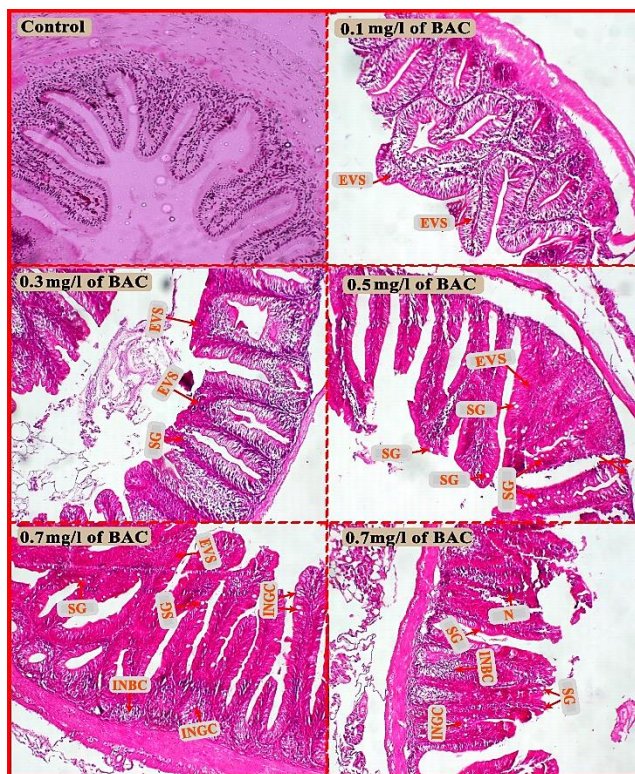

Fig. 5. Histological damage to the intestines of common carp after 28 days of exposure to benzalkonium chloride (BAC). (Control group: standard diet and water; Group B: 0.10 mg/L BAC; Group C: 0.32 mg/L BAC; Group D: 0.58 mg/L BAC; Group E: 0.75 mg/L BAC). The observed damage includes expansion of the villi structure (EVS), swelling of goblet cells (SG), an increase in the number of goblet cells (INGC), an increase in the number of blood cells (INBC), and necrosis (N).

Table 3. Histological damage to the intestines of common carp after 28 days of exposure to benzalkonium chloride (BAC). (Control group: standard diet and water; Group B: 0.10 mg/L BAC; Group C: 0.32 mg/L BAC; Group D: 0.58 mg/L BAC; Group E: 0.75 mg/L BAC). The observed damage includes expansion of the villi structure (EVS), swelling of goblet cells (SG), an increase in the number of goblet cells (INGC), an increase in the number of blood cells (INBC), and necrosis (N). No change (-), mild (+), moderate (++) and severe (+++).

Intestine	Histological changes				
	EVS	SG	INGC	INBC	N
Control	-	-	-	-	-
Group B	++	-	-	-	-
Group C	++	+	-	-	-
Group D	+++	++	-	-	-
Group E	+++	+++	++	++	+

3.7. Common carp liver histological damage

Fig. 6 illustrates the toxicity of BAC in the liver tissue of common carp after 28 days. Histological damage observed includes hepatocyte degeneration, rupture of the central vein wall, aggregation of melanomacrophages, and dilation of blood vessels. The most severe tissue damage occurs at a BAC concentration of 0.7 mg/L. The results indicate that BAC toxicity increases with higher concentrations (Table 4). In this study, the liver tissue of common carp exposed to high concentrations of BAC showed histopathological damage, including hepatocyte degeneration, rupture of

the central vein wall, and melano-macrophage aggregation. High concentrations of disinfectants like BAC can disrupt cellular metabolic processes, making the liver particularly vulnerable as it plays a key role in detoxification (Perez et al., 2009). BAC may increase ion permeability, reduce membrane fluidity, and cause necrosis in liver tissue by inducing oxidative stress (Christen et al., 2017). The generation of reactive oxygen species (ROS) is heightened by BAC hydrocarbons, leading to oxidative stress (Li, 2008). BAC's chemical properties can alter liver enzymes, disrupting their activity and impairing the enzyme defense system responsible for detoxification (Jee and Kang, 2005).

Previous studies have reported liver tissue damage in the frog *Bufo gargarizans* exposed to various concentrations of triclosan (Chai et al., 2017). Gheorghe et al. (2020) found that BAC caused cytoplasmic vacuolation and nuclear hypertrophy in common carp liver. Capkin et al. (2017) reported that triclosan

induced liver cell necrosis in rainbow trout, while Rodrigues et al. (2019) observed hepatocellular vacuolation, nuclear pyknosis, hepatocyte degeneration, and hemorrhage in *Oncorhynchus mykiss*. Dani et al. (2019) also noted melano-macrophage accumulation and hepatocellular congestion.

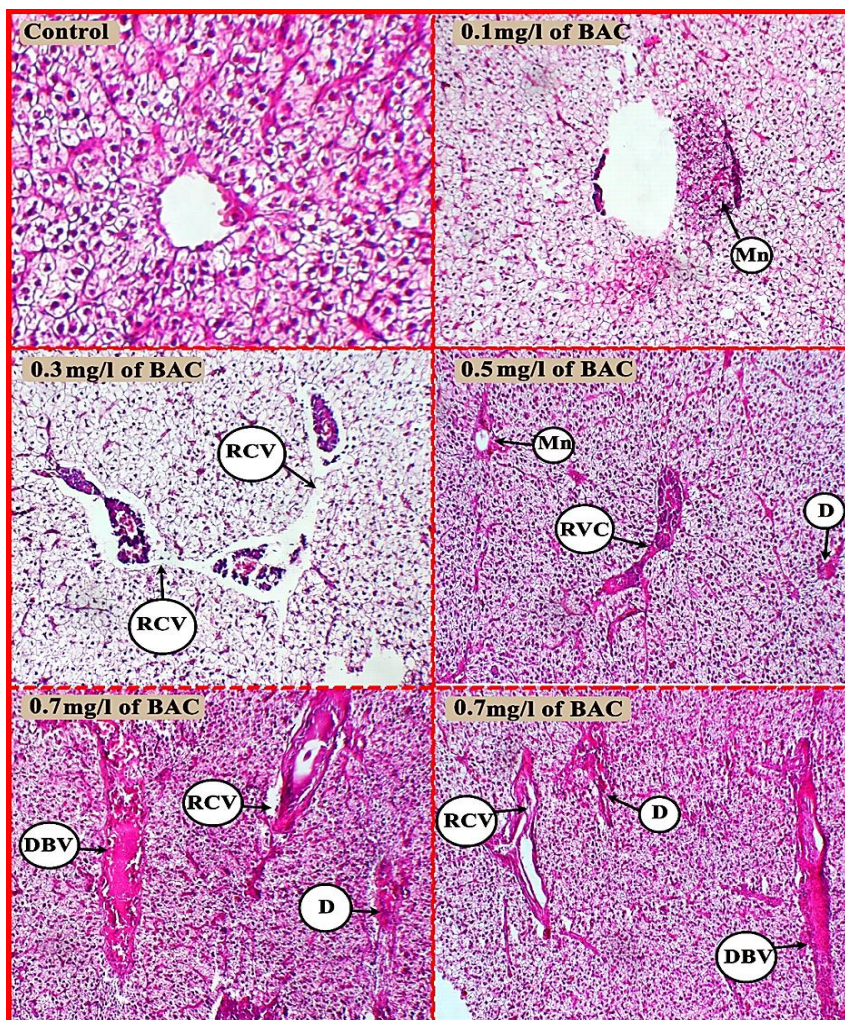


Fig. 6. Histological damage to the liver of common carp following 28 days of exposure to benzalkonium chloride (BAC). (Control group: standard diet and water; Group B: 0.10 mg/L BAC; Group C: 0.32 mg/L BAC; Group D: 0.58 mg/L BAC; Group E: 0.75 mg/L BAC). The observed damage includes hepatocyte degeneration (D), rupture of the central vein wall (RCV), dilation of blood vessels (DBV), and aggregation of melanomacrophages (Mn).

Table 4. Histological damage to the liver of common carp following 28 days of exposure to benzalkonium chloride (BAC). (Control group: standard diet and water; Group B: 0.10 mg/L BAC; Group C: 0.32 mg/L BAC; Group D: 0.58 mg/L BAC; Group E: 0.75 mg/L BAC). The observed damage includes hepatocyte degeneration (D), rupture of the central vein wall (RCV), dilation of blood vessels (DBV), and aggregation of melanomacrophages (Mn). No change (-), mild (+), moderate (++) and severe (+++).

Liver	Histological changes			
	D	RCV	DBV	Mn
Control	-	-	-	-
Group B	-	-	-	+
Group C	-	++	-	-
Group D	+	++	-	++
Group E	+++	++	++	-

4. Conclusion

The findings from this study underscore the toxicological impact of BAC on fish, particularly highlighting its detrimental effects on hematological, biochemical, and enzymatic parameters. BAC exposure results in significant reductions in red blood cells, hemoglobin, and hematocrit levels, while increasing white blood cell counts, indicating an immune response to stress and potential anemia. The biochemical analysis reveals lowered cholesterol and protein levels, coupled with elevated glucose, uric acid, and creatinine levels, reflecting metabolic disruptions and kidney damage. Additionally, increased levels of liver enzymes such as ALP, AST, and ALT suggest liver dysfunction and oxidative stress induced by BAC. These results collectively demonstrate that BAC, through its lipophilic nature and interaction with cellular membranes, poses significant risks to aquatic life by compromising vital physiological functions. Due to the fact that common carp is a mud-eater, the conditions of keeping them in laboratory conditions are very difficult. It is suggested to investigate the synergistic effects of BAC with other pollutants such as heavy metals, microplastics, herbicides and drugs on fish with different concentrations.

Acknowledgments

This article is taken from the research project with the number 1402/D/24047 of Research and Technology Deputy of University of Birjand. We are grateful for the financial and spiritual support of University of Birjand in conducting this research.

References

- Alkaladi, A., El-Deen, N. A. N., Afifi, M. & Zinadah, O.A.A., 2015. Hematological and biochemical investigations on the effect of vitamin E and C on *Oreochromis niloticus* exposed to zinc oxide nanoparticles. *Saudi Journal of Biological Sciences*, 22(5), 556-563.
- Abd El-Naby, A.S., Al-Sagheer, A.A., Negm, S.S. & Naiel, M.A., 2020. Dietary combination of chitosan nanoparticle and thymol affects feed utilization, digestive enzymes, antioxidant status, and intestinal morphology of *Oreochromis niloticus*. *Aquaculture*, 515, 734577.
- Arman, S., 2021. Effects of acute triclosan exposure on gill and liver tissues of zebrafish (*Danio rerio*). In *Annales de Limnologie-international journal of limnology* (Vol. 57, p. 6). EDP Sciences.
- adel Abdel-Khalek, A., Kadry, M., Hamed, A. & Marie, M.A., 2015. Ecotoxicological impacts of zinc metal in comparison to its nanoparticles in Nile tilapia; *Oreochromis niloticus*. *The Journal of Basic & Applied Zoology*, 72, 113-125.
- Akram, R., Ghaffar, A., Hussain, R., Khan, I., de Assis Santana, V.L., Mehmood, K. ... & Zhu, H., 2022. Hematological, serum biochemistry, histopathological and mutagenic impacts of triclosan on fish (bighead carp). *Agrobiological Records*, 7, 18-28.
- Akram, R., Iqbal, R., Hussain, R., Jabeen, F. & Ali, M., 2021. Evaluation of oxidative stress, antioxidant enzymes and genotoxic potential of bisphenol A in fresh water bighead carp (*Aristichthys nobilis*) fish at low concentrations. *Environmental Pollution*, 268, 115896.
- Antunes, S.C., Nunes, B., Rodrigues, S., Nunes, R., Fernandes, J. & Correia, A.T., 2016. Effects of chronic exposure to benzalkonium chloride in *Oncorhynchus mykiss*: cholinergic neurotoxicity, oxidative stress, peroxidative damage and genotoxicity. *Environmental Toxicology and Pharmacology*, 45, 115-122.
- Artacho, P., Soto-Gamboa, M., Verdugo, C. & Nespolo, R.F., 2007. Blood biochemistry reveals malnutrition in black-necked swans (*Cygnus melanocoryphus*) living in a conservation priority area. *Comparative Biochemistry and Physiology Part A: Molecular & Integrative Physiology*, 146(2), 283-290.
- Aboulhoda, B.E., Abdeltawab, D.A., Rashed, L.A., Abd Alla, M.F. & Yassa, H.D., 2020. Hepatotoxic Effect of Oral Zinc Oxide Nanoparticles and the Ameliorating Role of Selenium in Rats: A histological, immunohistochemical and molecular study. *Tissue and Cell*, 67, 101441.
- Antunes, S.C., Nunes, B., Rodrigues, S., Nunes, R., Fernandes, J. & Correia, A.T., 2016. Effects of chronic exposure to benzalkonium chloride in *Oncorhynchus mykiss*: cholinergic neurotoxicity, oxidative stress, peroxidative damage and genotoxicity. *Environmental Toxicology and Pharmacology*, 45, 115-122.
- Arianto, S.R., Syah, F.A., Sari, L.A., Nafisyah, A.L., Arsad, S. & Musa, N., 2023. Analyze the toxicities of benzalkonium chloride as a COVID-19 disinfectant in physiological goldfish (*Carassius auratus*). *Veterinary World*, 16(7), 1400.
- Bera, K.K., Kumar, S., Paul, T., Prasad, K.P., Shukla, S.P. & Kumar, K., 2020. Triclosan induces immunosuppression and reduces survivability of striped catfish *Pangasianodon hypophthalmus* during the challenge to a fish pathogenic bacterium *Edwardsiella tarda*. *Environmental Research*, 186, 109575.
- Bongers, A.B.J., Sukkel, M., Gort, G., Komen, J. & Richter, C.J.J., 1998. Development and use of genetically uniform strains of common carp in experimental animal research. *Laboratory Animals*, 32(4), 349-363.
- Choi, H.Y., Lee, Y.H., Lim, C.H., Kim, Y.S., Lee, I.S., Jo, J.M. ... & Seo, D.S., 2020. Assessment of respiratory and systemic toxicity of Benzalkonium chloride following a 14-day inhalation study in rats. *Particle and Fibre Toxicology*, 17, 1-19.
- Christen, V., Faltermann, S., Brun, N.R., Kunz, P.Y. & Fent, K., 2017. Cytotoxicity and molecular effects of biocidal disinfectants (quaternary ammonia, glutaraldehyde, poly (hexamethylene biguanide)

- hydrochloride PHMB) and their mixtures in vitro and in zebrafish eleuthero-embryos. *Science of the Total Environment*, 586, 1204-1218.
- Chupani, L., Zuskova, E., Niksirat, H., Panacek, A., Lünsmann, V., Haange, S.B. ... & Jehmlich, N., 2017. Effects of chronic dietary exposure of zinc oxide nanoparticles on the serum protein profile of juvenile common carp (*Cyprinus carpio* L.). *Science of The Total Environment*, 579, 1504-1511.
- Curi, L.M., Peltzer, P.M., Sandoval, M.T. & Lajmanovich, R.C., 2019. Acute toxicity and sublethal effects caused by a commercial herbicide formulated with 2, 4-D on *Physalaemus albonotatus* tadpoles. *Water, Air, & Soil Pollution*, 230, 1-15.
- de Souza, T.A.J., Souza, L.R.R. & Franchi, L.P., 2019. Silver nanoparticles: An integrated view of green synthesis methods, transformation in the environment, and toxicity. *Ecotoxicology and Environmental Safety*, 171, 691-700.
- Capkin, E., Ozelepe, T., Kayis, S. & Altinok, I., 2017. Antimicrobial agents, triclosan, chloroxylenol, methylisothiazolinone and borax, used in cleaning had genotoxic and histopathologic effects on rainbow trout. *Chemosphere*, 182, 720-729.
- Chai, L., Chen, A., Luo, P., Zhao, H. & Wang, H., 2017. Histopathological changes and lipid metabolism in the liver of *Bufo gargarizans* tadpoles exposed to Triclosan. *Chemosphere*, 182, 255-266.
- Clara, M., Scharf, S., Scheffknecht, C. & Gans, O., 2007. Occurrence of selected surfactants in untreated and treated sewage. *Water Research*, 41(19), 4339-4348.
- Dar, O.I., Vinothkanna, A., Aslam, B., Furkh, A., Sharma, S., Kaur, A. ... & Jia, A.Q., 2024. Dynamic alterations in physiological and biochemical indicators of *Cirrhinus mrigala* hatchlings: A sublethal exposure of triclosan. *Science of The Total Environment*, 924, 171701.
- Dani, U., Bahadur, A. & Kuperkar, K., 2019. Biototoxicity and tissue-specific oxidative stress induced by Gemini surfactant as a protocol on fingerlings of *Cirrhinus mrigala* (Ham.): An integrated experimental and theoretical methodology. *Ecotoxicology and Environmental Safety*, 183, 109478.
- Dar, O.I., Sharma, S., Singh, K., Sharma, A., Bhardwaj, R. & Kaur, A., 2020a. Biomarkers for the toxicity of sublethal concentrations of triclosan to the early life stages of carps. *Scientific Reports*, 10(1), 17322.
- Dar, O. I., Sharma, S., Singh, K., Sharma, A., Bhardwaj, R. & Kaur, A., 2020b. Biochemical markers for prolongation of the acute stress of triclosan in the early life stages of four food fishes. *Chemosphere*, 247, 125914.
- Das, A. & Mohanty, P.K., 2018. Comparative hemocytobiochemical profile of *Rattus rattus* Linnaeus, 1758 and *Rattus norvegicus* Berkenhout, 1769. *Comparative Clinical Pathology*, 27, 1509-1514.
- Elkeiy, M.M., Khamis, A.A., El-Gamal, M.M., Abo Gazia, M.M., Zalat, Z.A. & El-Magd, M.A., 2020. Chitosan nanoparticles from *Artemia salina* inhibit progression of hepatocellular carcinoma in vitro and in vivo. *Environmental Science and Pollution Research*, 27, 19016-19028.
- Food and Drug Administration, H.H.S., 2016. Safety and effectiveness of consumer antiseptics; topical antimicrobial drug products for over-the-counter human use. Final rule. *Federal Register*, 81(172), 61106-61130.
- Ferk, F., Misik, M., Hoelzl, C., Uhl, M., Fuerhacker, M., Grillitsch, B. ... & Knasmüller, S., 2007. Benzalkonium chloride (BAC) and dimethyldioctadecyl-ammonium bromide (DDAB), two common quaternary ammonium compounds, cause genotoxic effects in mammalian and plant cells at environmentally relevant concentrations. *Mutagenesis*, 22(6), 363-370.
- Gouda, A.M., Hagra, A.E., Okbah, M.A. & El-Gammal, M.I., 2022. Influence of the Linear Alkylbenzene Sulfonate (LAS) on hematological and biochemical parameters of Nile Tilapia, *Oreochromis niloticus*. *Saudi Journal of Biological Sciences*, 29(2), 1006-1013.
- Giang, P.T., Burkina, V., Sakalli, S., Schmidt-Posthaus, H., Rasmussen, M.K., Randak, T. ... & Zlabek, V., 2019. Effects of multi-component mixtures from sewage treatment plant effluent on common carp (*Cyprinus carpio*) under fully realistic condition. *Environmental Management*, 63, 466-484.
- Ghaffar, A., Hussain, R., Abbas, G., Kalim, M., Khan, A., Ferrando, S. ... & Ahmed, Z., 2018. Fipronil (Phenylpyrazole) induces hemato-biochemical, histological and genetic damage at low doses in common carp, *Cyprinus carpio* (Linnaeus, 1758). *Ecotoxicology*, 27, 1261-1271.
- Ghaffar, A., Hussain, R., Ahmad, N., Ghafoor, R., Akram, M.W., Khan, I. & Khan, A., 2021. Evaluation of hemato-biochemical, antioxidant enzymes as biochemical biomarkers and genotoxic potential of glyphosate in freshwater fish (*Labeo rohita*). *Chemistry and Ecology*, 37(7), 646-667.
- Gheorghie, S., Mitroi, D.N., Stan, M.S., Staicu, C.A., Cicirma, M., Lucaciu, I.E. ... & Dinischiotu, A., 2020. Evaluation of sub-lethal toxicity of benzethonium chloride in *Cyprinus carpio* liver. *Applied Sciences*, 10(23), 8485.
- Hedayati, S.A., Farsani, H.G., Naserabad, S.S., Hoseinifar, S.H. & Van Doan, H., 2019. Protective effect of dietary vitamin E on immunological and biochemical induction through silver nanoparticles (AgNPs) inclusion in diet and silver salt (AgNO₃) exposure on Zebrafish (*Danio rerio*). *Comparative Biochemistry and Physiology Part C: Toxicology & Pharmacology*, 222, 100-107.
- Hora, P.I., Pati, S.G., McNamara, P.J. & Arnold, W.A., 2020. Increased use of quaternary ammonium compounds during the SARS-CoV-2 pandemic and beyond: consideration of environmental implications. *Environmental Science & Technology Letters*, 7(9), 622-631.
- Hatami, M., Banaee, M. & Haghi, B.N., 2019. Sub-lethal toxicity of chlorpyrifos alone and in combination with polyethylene glycol to common carp (*Cyprinus carpio*). *Chemosphere*, 219, 981-988.
- Hemalatha, D., Rangasamy, B., Nataraj, B. & Ramesh, M., 2019. Assessment of triclosan impact on enzymatic biomarkers in an Indian major carp, *Catla catla*. *The Journal of Basic and Applied Zoology*, 80, 1-8.
- Ikisa, K.G., Babatunde, B.B. & Hart, A.I., 2019. Histopathological variations in gills, liver and kidney of Nile tilapia-*Oreochromis niloticus* exposed to benzalkoniumchloride mixture with treated

- produced water. *Journal of Applied Sciences and Environmental Management*, 23(6), 1181-1187.
- Julinta, R.B., Abraham, T.J., Roy, A., Singha, J., Boda, S. & Patil, P.K., 2019. Dietary influences of oxytetracycline on the growth and serum biomarkers of *Oreochromis niloticus* (L.). *Ecotoxicology and Environmental Safety*, 186, 109752.
- Johari, S.A., Kalbassi, M.R., Yu, I.J. & Lee, J.H., 2015. Chronic effect of waterborne silver nanoparticles on rainbow trout (*Oncorhynchus mykiss*): histopathology and bioaccumulation. *Comparative Clinical Pathology*, 24, 995-1007.
- Jee, J.H. & Kang, J.C., 2005. Biochemical changes of enzymatic defense system after phenanthrene exposure in olive flounder, *Paralichthys olivaceus*. *Physiological Research*, 54(585), e591.
- Kaya, H., Celik, E.S., Yılmaz, S., Tulgar, A., Akbulut, M. & Demir, N., 2015. Hematological, serum biochemical, and immunological responses in common carp (*Cyprinus carpio*) exposed to phosalone. *Comparative Clinical Pathology*, 24, 497-507.
- Kaya, H., Aydın, F., Gurkan, M., Yılmaz, S., Ates, M., Demir, V. & Arslan, Z., 2016. A comparative toxicity study between small and large size zinc oxide nanoparticles in tilapia (*Oreochromis niloticus*): Organ pathologies, osmoregulatory responses and immunological parameters. *Chemosphere*, 144, 571-582.
- Kakakhel, M.A., Wu, F., Sajjad, W., Zhang, Q., Khan, I., Ullah, K. & Wang, W., 2021. Long-term exposure to high-concentration silver nanoparticles induced toxicity, fatality, bioaccumulation, and histological alteration in fish (*Cyprinus carpio*). *Environmental Sciences Europe*, 33, 1-11.
- Kaczmarewska, O., Martins, R., Figueiredo, J., Loureiro, S. & Tedim, J., 2020. Environmental behaviour and ecotoxicity of cationic surfactants towards marine organisms. *Journal of Hazardous Materials*, 392, 122299.
- Kwon, D., Kwon, J.T., Lim, Y.M., Shim, I., Kim, E., Lee, D.H. ... & Kim, H.M., 2019. Inhalation toxicity of benzalkonium chloride and triethylene glycol mixture in rats. *Toxicology and Applied Pharmacology*, 378, 114609.
- Kwon, Y.S., Jung, J. W., Kim, Y.J., Park, C.B., Shon, J.C., Kim, J.H. ... & Seo, J.S., 2020. Proteomic analysis of whole-body responses in medaka (*Oryzias latipes*) exposed to benzalkonium chloride. *Journal of Environmental Science and Health, Part A*, 55(12), 1387-1397.
- Kandel, I. & Castelli, M., 2020. A novel architecture to classify histopathology images using convolutional neural networks. *Applied Sciences*, 10(8), 2929.
- Lavorgna, M., Russo, C., D'Abrosca, B., Parrella, A. & Isidori, M., 2016. Toxicity and genotoxicity of the quaternary ammonium compound benzalkonium chloride (BAC) using *Daphnia magna* and *Ceriodaphnia dubia* as model systems. *Environmental Pollution*, 210, 34-39.
- Li, M.H., 2008. Effects of nonionic and ionic surfactants on survival, oxidative stress, and cholinesterase activity of planarian. *Chemosphere*, 70(10), 1796-1803.
- Lakra, K.C., Banerjee, T.K. & Lal, B., 2021. Coal mine effluent-induced metal bioaccumulation, biochemical, oxidative stress, metallothionein, and histopathological alterations in vital tissues of the catfish, *Clarias batrachus*. *Environmental Science and Pollution Research*, 28, 25300-25315.
- Li, W., Zhang, W., Chang, M., Ren, J., Xie, W., Chen, H. ... & Li, H., 2018. Metabonomics reveals that triclocarban affects liver metabolism by affecting glucose metabolism, β -oxidation of fatty acids, and the TCA cycle in male mice. *Toxicology Letters*, 299, 76-85.
- Merchel Piovesan Pereira, B. & Tagkopoulos, I., 2019. Benzalkonium chlorides: uses, regulatory status, and microbial resistance. *Applied and Environmental Microbiology*, 85(13), e00377-19.
- Mentese, E., & Hancer, E., 2020. Histopatoloji görüntülerde derin öğrenme yöntemleri ile çekirdek segmentasyonu. *Avrupa Bilim ve Teknoloji Dergisi*, 95-102.
- Martinez-Carballo, E., Sitka, A., Gonzalez-Barreiro, C., Kreuzinger, N., Furrhacker, M., Scharf, S. & Gans, O., 2007. Determination of selected quaternary ammonium compounds by liquid chromatography with mass spectrometry. Part I. Application to surface, waste and indirect discharge water samples in Austria. *Environmental Pollution*, 145(2), 489-496.
- Mansouri, B., Maleki, A., Johari, S.A., Shahmoradi, B., Mohammadi, E. & Davari, B., 2017. Histopathological effects of copper oxide nanoparticles on the gill and intestine of common carp (*Cyprinus carpio*) in the presence of titanium dioxide nanoparticles. *Chemistry and Ecology*, 33(4), 295-308.
- Nan, Y., Zhu, X., Huang, J., Zhang, Z., Xing, Y., Yang, Y. ... & Duan, Y., 2023. Toxic effects of triclocarban on the histological morphology, physiological and immune response in the gills of the black tiger shrimp *Penaeus monodon*. *Marine Environmental Research*, 192, 106245.
- Owonikoko, M.W., Salami, A.T., Odukanmi, A.O., Emikpe, B.O. & Olaleye, S.B., 2022. Hematopoietic toxicity in wistar rats experimentally exposed to cement dust. *Comparative Clinical Pathology*, 31(2), 181-199.
- O'Brown, N.M., Pfau, S.J. & Gu, C., 2018. Bridging barriers: a comparative look at the blood-brain barrier across organisms. *Genes & Development*, 32(7-8), 466-478.
- OECD., 2019. OECD Guidelines for the Testing of Chemicals, Section 2: Effects on Biotic Systems, Test guideline No. 203: Fish, Acute Toxicity Testing. OECD Publishing, <https://doi.org/10.1787/20745761>.
- Pourahmad, J., Salami, M. & Zarei, M.H., 2023. Comparative toxic effect of bulk copper oxide (CuO) and CuO nanoparticles on human red blood cells. *Biological Trace Element Research*, 201(1), 149-155.
- Perez, P., Fernandez, E. & Beiras, R., 2009. Toxicity of benzalkonium chloride on monoalgal cultures and natural assemblages of marine phytoplankton. *Water, Air, and Soil Pollution*, 201, 319-330.
- Penuela, G. A., & Martinez-Lopez, E., 2021. Enzymatic activity changes in striped catfish *Pseudoplatystoma magdaleniatum*, induced by exposure to different concentrations of ibuprofen and triclosan. *Chemosphere*, 271, 129399.

- Pane, E.F., Haque, A. & Wood, C.M., 2004. Mechanistic analysis of acute, Ni-induced respiratory toxicity in the rainbow trout (*Oncorhynchus mykiss*): an exclusively branchial phenomenon. *Aquatic Toxicology*, 69(1), 11-24.
- Priyatha, C.V. & Chitra, K.C., 2018. Acute toxicity of triclosan on the native freshwater fish, *Anabas testudineus* (Bloch, 1792): behavioral alterations and histopathological lesions. *International Journal of Life Sciences*, 6(1), 166-172.
- Rodrigues, S., Antunes, S.C., Nunes, B. & Correia, A.T., 2019. Histopathological effects of the antibiotic erythromycin on the freshwater fish species *Oncorhynchus mykiss*. *Ecotoxicology and Environmental Safety*, 181, 1-10.
- Sharma, S., Dar, O.I., Singh, K., Kaur, A. & Faggio, C., 2021. Triclosan elicited biochemical and transcriptomic alterations in *Labeo rohita* larvae. *Environmental Toxicology and Pharmacology*, 88, 103748.
- Said, R.E., Abd-ElRaouf, M.H., Moustafa, M.A. & Badrey, A.E., 2023. Hemato-Serological Findings as Early signals in Nile Tilapia *Oreochromis niloticus* Treated with Benzalkonium Chloride. *Baghdad Science Journal*, 20(3 (Suppl.)), 0945-0945.
- Shaluei, F., Hedayati, A., Jahanbakhshi, A., Kolangi, H. & Fotovat, M., 2013. Effect of subacute exposure to silver nanoparticle on some hematological and plasma biochemical indices in silver carp (*Hypophthalmichthys molitrix*). *Human & Experimental Toxicology*, 32(12), 1270-1277.
- Suganthi, P., Murali, M., Sadiq Bukhari, A., Syed Mohamed, H.E., Basu, H. & Singhal, R.K., 2015. Behavioural and Histological variations in *Oreochromis mossambicus* after exposure to ZnO Nanoparticles. *International Journal of Applied Research*, 1(8), 524-31.
- Saravanan, M., Karthika, S., Malarvizhi, A. & Ramesh, M., 2011. Ecotoxicological impacts of clofibric acid and diclofenac in common carp (*Cyprinus carpio*) fingerlings: hematological, biochemical, ionoregulatory and enzymological responses. *Journal of Hazardous Materials*, 195, 188-194.
- Tuncsoy, M., 2021. Impacts of titanium dioxide nanoparticles on serum parameters and enzyme activities of *Clarias gariepinus*. *Bulletin of Environmental Contamination and Toxicology*, 106(4), 629-636.
- Vasantharaja, D., Ramalingam, V. & Reddy, G.A., 2015. Oral toxic exposure of titanium dioxide nanoparticles on serum biochemical changes in adult male Wistar rats. *Nanomedicine Journal*, 2(1).
- Vijitha, C.K., Asifa, K.P. & Chitra, K.C., 2017. Assessment of genotoxic and haematological consequence of triclosan in the fish, *Oreochromis niloticus* (Linnaeus, 1758). *International Journal of Applied Research*, 3(2), 101-109.
- Yahya, R.A., Attia, A.M., El-Banna, S.G., El-Trass, E.E., Azab, A.E., Jbireal, J.M. & Shkal, K.E.M., 2019. Hematotoxicity induced by copper oxide and/or zinc oxide nanoparticles in male albino rats. *Journal Biotechnol*, 3(4), 1-7.
- Zheng, H., Mortensen, L.J. & DeLouise, L.A., 2013. Thiol antioxidant-functionalized CdSe/ZnS quantum dots: synthesis, characterization, cytotoxicity. *Journal of Biomedical Nanotechnology*, 9(3), 382-392.
- Zheng, G., Filippelli, G.M. & Salamova, A., 2020. Increased indoor exposure to commonly used disinfectants during the COVID-19 pandemic. *Environmental Science & Technology Letters*, 7(10), 760-765.
- Zhang, C., Cui, F., Zeng, G.M., Jiang, M., Yang, Z.Z., Yu, Z.G. ... & Shen, L.Q., 2015. Quaternary ammonium compounds (QACs): A review on occurrence, fate and toxicity in the environment. *Science of the Total Environment*, 518, 352-362.
- Zhang, L., Yang, Z., Yang, M., Yang, F., Wang, G., Liu, D. ... & Wang, Z., 2022. Copper-induced oxidative stress, transcriptome changes, intestinal microbiota, and histopathology of common carp (*Cyprinus carpio*). *Ecotoxicology and Environmental Safety*, 246, 114136.
- Zhang, C., Cui, F., Zeng, G.M., Jiang, M., Yang, Z.Z., Yu, Z.G. ... & Shen, L.Q., 2015. Quaternary ammonium compounds (QACs): A review on occurrence, fate and toxicity in the environment. *Science of the Total Environment*, 518, 352-362.